UMC Utrecht

Hoe ziet de IBD-zorg eruit over 10 jaar?

Prof. dr. B. Oldenburg

radison
adelaide
hospital

© ClassicStock/Corbis

Oorzaak van IBD

Oorzaak van IBD

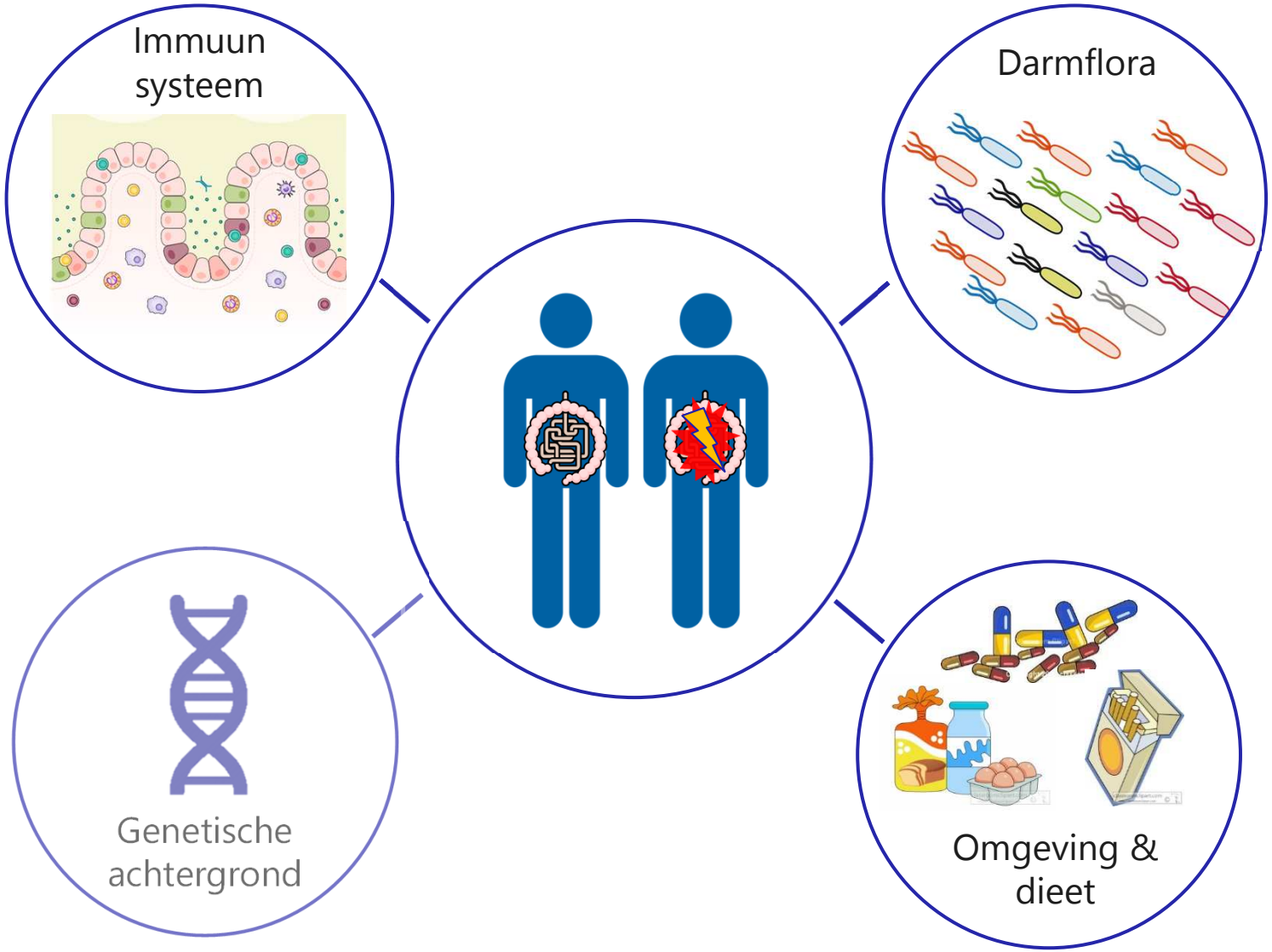

Oorzaak van IBD

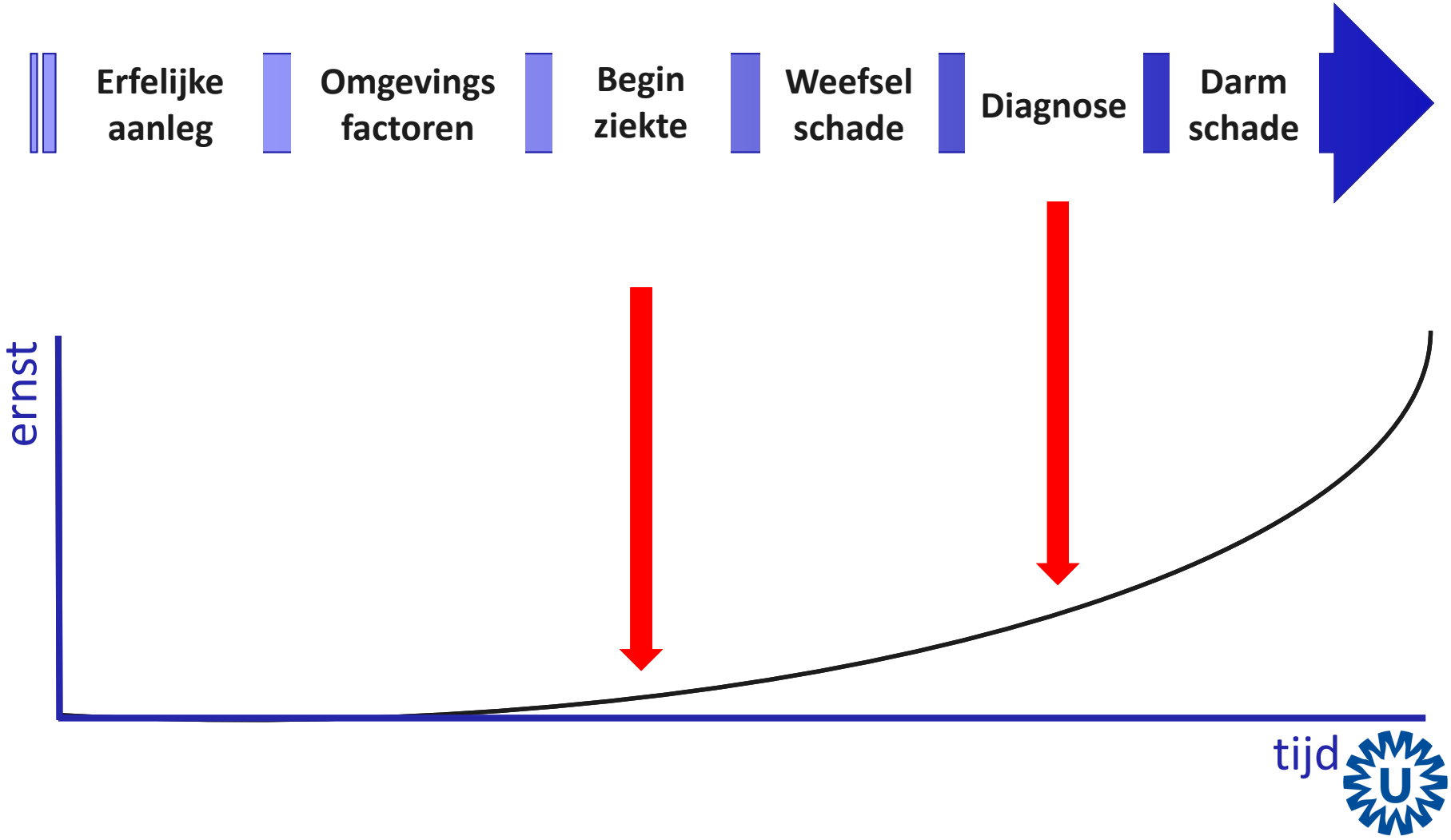

Oorzaak van IBD

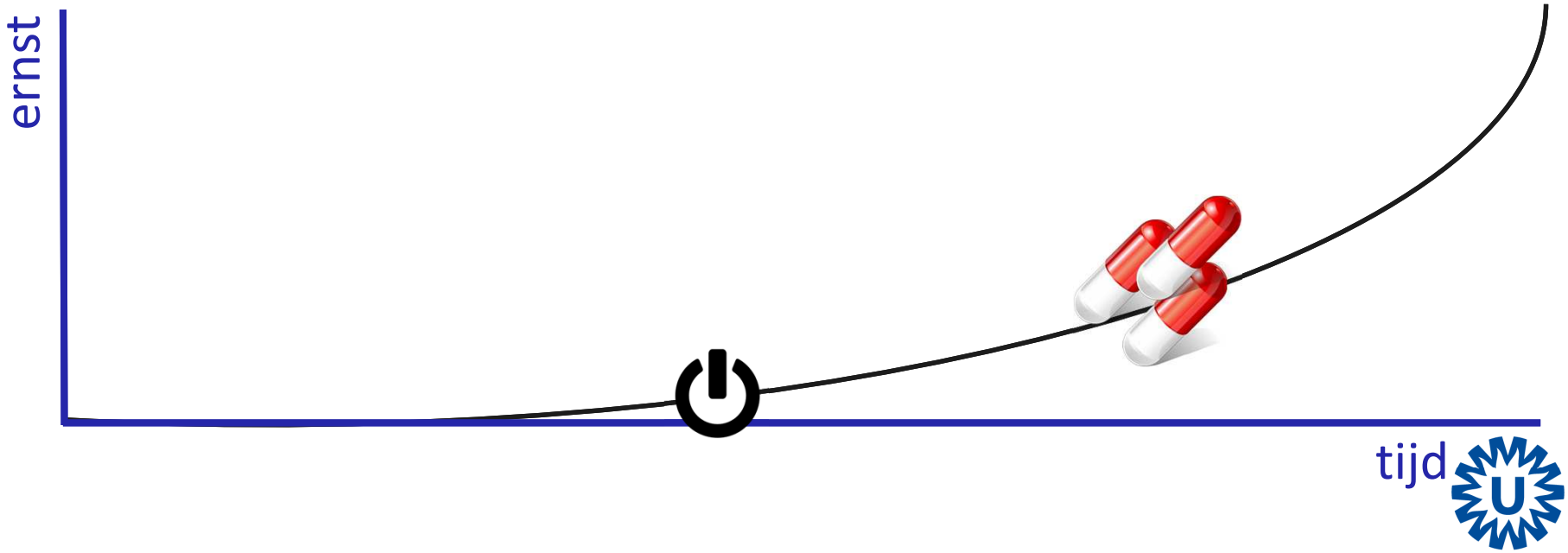

Voorkomen van IBD?



Diagnose

Therapy

Diagnose van IBD

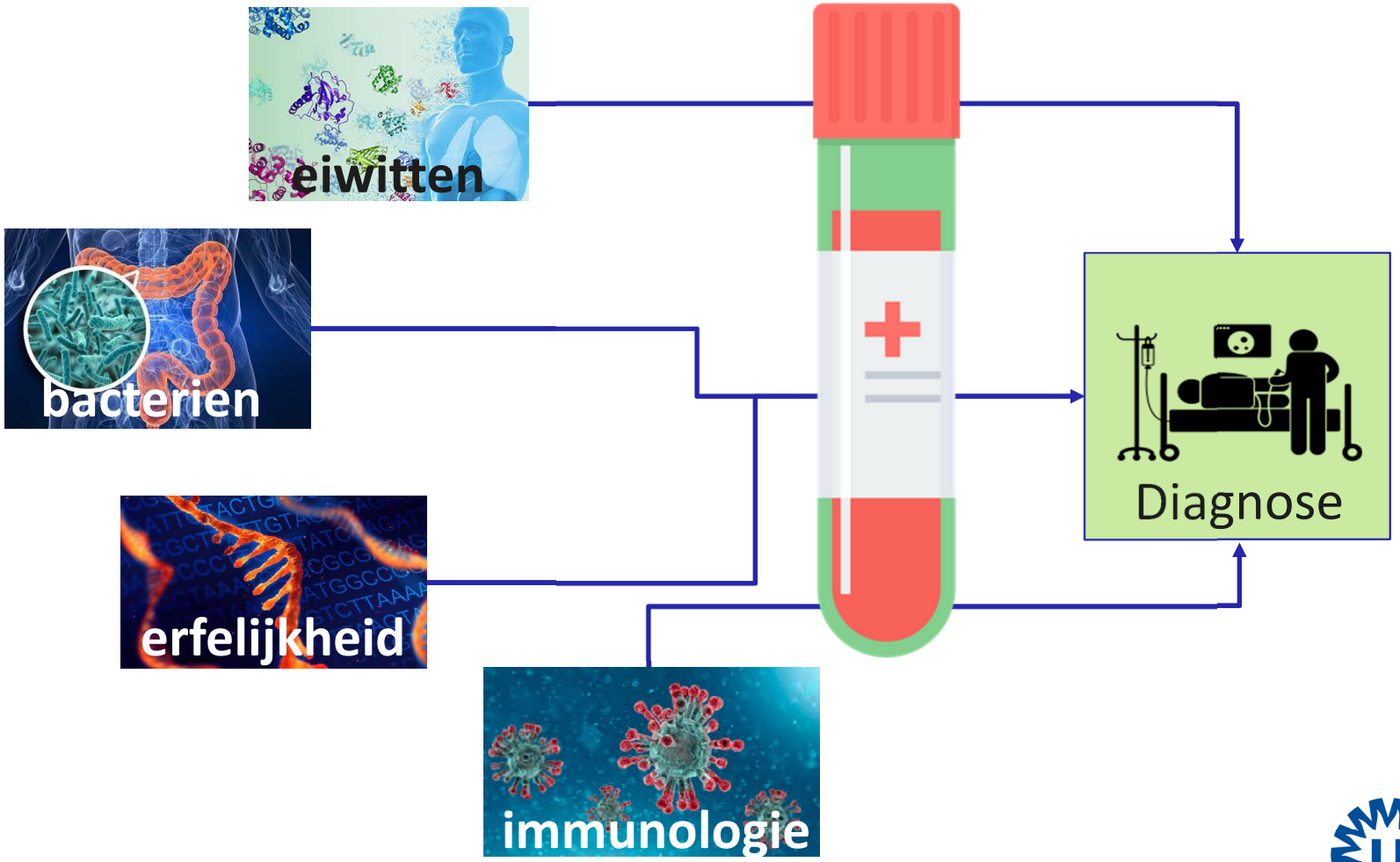

Controleren van IBD



Controleren van IBD

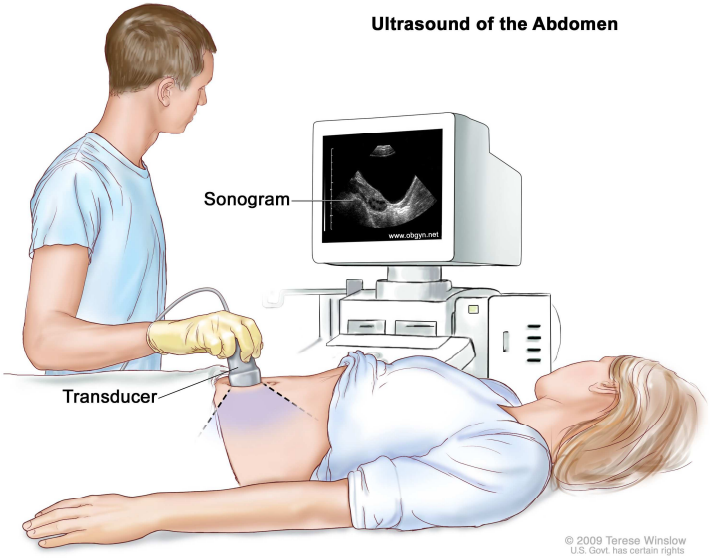

Statement 28. We suggest that cross-sectional imaging, specifically MRI, CT and ultrasound, have largely replaced conventional barium fluoroscopic and nuclear medicine techniques and have the advantage of evaluating both luminal and extraluminal disease. Emphasis should be placed on MR enterography and ultrasound as they do not expose patients to ionising radiation (GRADE: weak recommendation, moderate-quality evidence. Agreement: 97.9%).

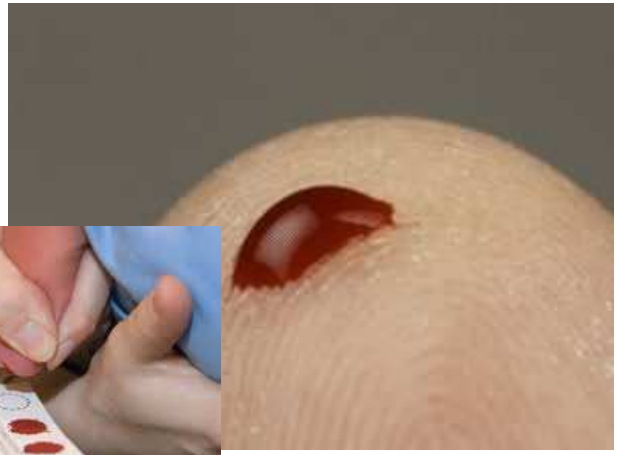

Behandeling van IBD

vedolizumab

imuran

Medicament y

prednison

thiosix

Medicament x

purinethol

golimumab

adalimumab

methotrexaat

infliximab

mesalazine

budesonide

tofacitinib

Medicament z

ustekinumab

sulfasalazine

Behandeling van IBD

Behandeling van IBD

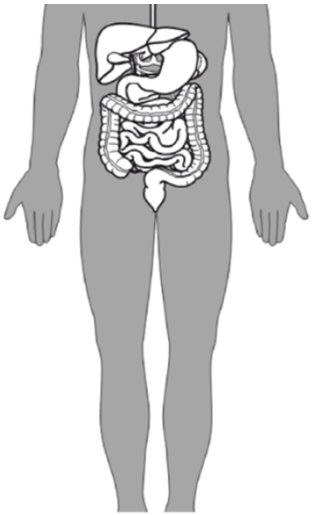

Imaging technologies
- Endoscopy
- CT Enterography
- MR Enterography
- GI ultrasound
- Histopathology

High throughput omics data
- Genomics
- Epigenomics
- Transcriptomics

Artificial intelligence
- Language processing
- Machine learning
  - Unsupervised learning
    - Clustering (e.g. PCA)
  - Supervised learning
    - Classification and regression (e.g. RF)
- Deep learning

Systems Biology
- Biological network construction

Behandeling van IBD

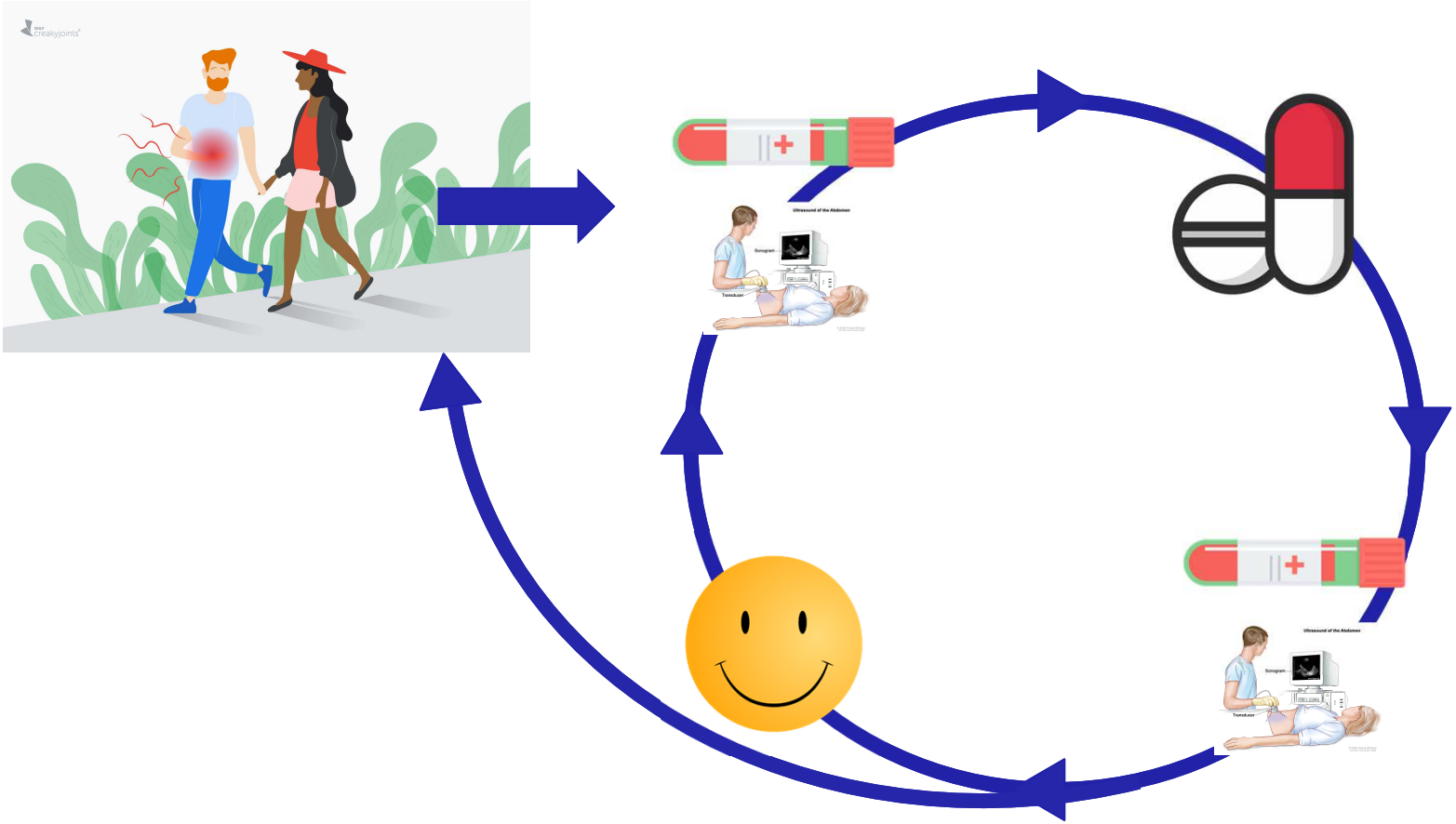

IBD over 10 jaar:

- Eerdere diagnose stelling
- Eerdere behandeling waardoor ziekte milder verloopt

- Diagnostiek waarbij het endoscopisch darmonderzoek een minder grote rol gaat spelen
- Controles om opvlammingen te *voorkomen*

- Profilering van patienten waardoor betere inzet van behandeling

FOKKE & SUKKE
SNAPPEN NIET WAAR DIE BUIKKLACHTEN VANDAAN KOMEN
EN NU BEN JE ÓÓK NOG GEZAKT...
...VOOR JE FECAAL-CALPROTECTINETEST!
RGvT